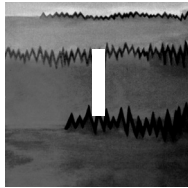


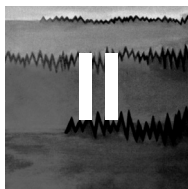
CHAPTER



● Metabolic, toxic and other encephalopathies

I• 1	Metabolic encephalopathy: acute renal failure (1)	18	I• 20	Wernicke encephalopathy	56
I• 2	Metabolic encephalopathy: acute renal failure (2)	20	I• 21	Metabolic encephalopathy: acido-ketosis	58
I• 3	Metabolic encephalopathy: acute renal failure (3)	22	I• 22	Hyponatremia	60
I• 4	Metabolic encephalopathy: acute renal failure (4)	24	I• 23	Hypernatremia	62
I• 5	Metabolic encephalopathy: acute renal failure (5)	26	I• 24	Hypercalcemia	64
I• 6	Metabolic encephalopathy: acute renal failure (6)	28	I• 25	Severe hypophosphatemia-induced status epilepticus	66
I• 7	Sepsis-associated encephalopathy	30	I• 26	Hypoglycemic brain damage	68
I• 8	Metabolic and sepsis-associated encephalopathy (1)	32	I• 27	Myxedema with coma	70
I• 9	Metabolic and sepsis-associated encephalopathy (2)	34	I• 28	Hypercapnic encephalopathy syndrome (1)	72
I• 10	Valproate-induced hyperammonemic encephalopathy (1)	36	I• 29	Hypercapnic encephalopathy syndrome (2)	74
I• 11	Valproate-induced hyperammonemic encephalopathy (2)	38	I• 30	Respiratory failure: hypoxemia	76
I• 12	Hyperammonemic encephalopathy in an adult with Ornithine TransCarbamylase deficiency	40	I• 31	Toxic encephalopathy: topiramate	78
I• 13	Metabolic encephalopathy: acute liver failure in an infant	42	I• 32	Toxic encephalopathy: amoxicillin	80
I• 14	Metabolic encephalopathy: hepatic encephalopathy (1)	44	I• 33	Toxic encephalopathy: cefepime	82
I• 15	Metabolic encephalopathy: hepatic encephalopathy (2)	46	I• 34	Toxic encephalopathy: lithium (1)	84
I• 16	Metabolic encephalopathy: hepatic encephalopathy (3)	48	I• 35	Toxic encephalopathy: lithium (2)	86
I• 17	Hepatic encephalopathy with coma and status epilepticus (1)	50	I• 36	Toxic encephalopathy: lithium (3)	88
I• 18	Hepatic encephalopathy with coma and status epilepticus (2)	52	I• 37	Toxic encephalopathy: lithium (4)	90
I• 19	Hepatic encephalopathy with coma and status epilepticus (3)	54	I• 38	Toxic encephalopathy: neuroleptic malignant syndrome	92
			I• 39	Toxic encephalopathy: baclofen (1)	94
			I• 40	Toxic encephalopathy: baclofen (2)	96
			I• 41	Toxic encephalopathy: melphalan	98
			I• 42	Toxic encephalopathy: ifosfamide	100
			I• 43	Toxic encephalopathy: chloralose	102

CHAPTER




● Inflammation, infectious and auto-immune diseases

II• 1	Viral meningitis in a child	106	II• 15	Herpes simplex encephalitis: status epilepticus (2)	134
II• 2	Viral meningitis in an adult	108	II• 16	Herpesvirus-6 limbic encephalitis: non-convulsive focal status epilepticus (1)	136
II• 3	Late-onset group B streptococcal meningitis	110	II• 17	Herpesvirus-6 limbic encephalitis: non-convulsive focal status epilepticus (2)	138
II• 4	Pneumococcal meningitis with vasculitis (1)	112	II• 18	Epstein-Barr virus encephalitis	140
II• 5	Pneumococcal meningitis with vasculitis (2)	114	II• 19	Acute encephalitis (1)	142
II• 6	Neurocysticercosis with meningitis	116	II• 20	Acute encephalitis (2)	144
II• 7	Leptomeningeal carcinomatosis (1)	118	II• 21	Acute disseminated encephalomyelitis (ADEM) (1)	146
II• 8	Carcinomatous meningoencephalitis	120	II• 22	Acute disseminated encephalomyelitis (ADEM) (2)	148
II• 9	Immunosuppressant drug-induced aseptic meningoencephalitis	122	II• 23	Subacute sclerosing panencephalitis (1)	150
II• 10	Herpes simplex encephalitis (1)	124	II• 24	Subacute sclerosing panencephalitis (2)	152
II• 11	Herpes simplex encephalitis (2)	126	II• 25	LG11-antibody encephalitis	154
II• 12	Herpes simplex encephalitis (3)	128	II• 26	Faciobrachial dystonic seizures in a patient LG11-antibody encephalitis	156
II• 13	Herpes simplex encephalitis (4)	130			
II• 14	Herpes simplex encephalitis: status epilepticus (1)	132			

II• 27	Anti-NMDA receptor encephalitis (1)	158	II• 30	Progressive multifocal leukoencephalopathy	164
II• 28	Anti-NMDA receptor encephalitis (2)	160	II• 31	Brain abscess: non-convulsive focal status epilepticus	166
II• 29	Anti-Hu associated encephalitis	162	II• 32	Brain abscess: aphasic status epilepticus	168

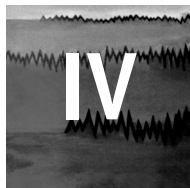
CHAPTER



● Vascular disorders

III• 1	Acute ischemic stroke in a child	172	III• 22	Arteriovenous malformation: non-convulsive focal status epilepticus (1)	214
III• 2	Acute ischemic stroke in an adult	174	III• 23	Arteriovenous malformation: non-convulsive focal status epilepticus (2)	216
III• 3	Acute ischemic stroke and status epilepticus (1)	176	III• 24	Moyamoya disease (1)	218
III• 4	Acute ischemic stroke and status epilepticus (2)	178	III• 25	Moyamoya disease (2)	220
III• 5	Acute ischemic stroke and status epilepticus (3)	180	III• 26	Cerebral amyloid angiopathy-related inflammation (1)	222
III• 6	Brain hematoma	182	III• 27	Cerebral amyloid angiopathy-related inflammation (2)	224
III• 7	Brain hematoma: focal motor status epilepticus	184	III• 28	Cerebral autosomal dominant arteriopathy with subcortical infarcts and leukoencephalopathy (CADASIL)	226
III• 8	Brain hematoma: electroencephalographic status epilepticus in coma (1)	186	III• 29	Mitochondrial encephalomyopathy, lactic acidosis, and stroke-like episodes (MELAS) (1)	228
III• 9	Brain hematoma: electroencephalographic status epilepticus in coma (2)	188	III• 30	Mitochondrial encephalomyopathy, lactic acidosis, and stroke-like episodes (MELAS) (2)	230
III• 10	Post-stroke epilepsy: <i>epilepsia partialis continua</i>	190	III• 31	Mitochondrial encephalomyopathy, lactic acidosis, and stroke-like episodes (MELAS) (3)	232
III• 11	Post-stroke epilepsy: cluster of seizure	192	III• 32	Mitochondrial encephalomyopathy, lactic acidosis, and stroke-like episodes (MELAS) (4)	234
III• 12	Thrombophlebitis	194	III• 33	Mitochondrial encephalomyopathy, lactic acidosis, and stroke-like episodes (MELAS) (5)	236
III• 13	Thrombophlebitis: aphasic status epilepticus	196	III• 34	Vasovagal syncope during sleep	238
III• 14	Vasospasm (1)	198	III• 35	Lance-Adams syndrome (1)	240
III• 15	Vasospasm (2)	200	III• 36	Lance-Adams syndrome (2)	242
III• 16	Gas embolism (1)	202			
III• 17	Gas embolism: status epilepticus with minor motor signs	204			
III• 18	Posterior reversible encephalopathy syndrome (PRES)	206			
III• 19	Posterior reversible encephalopathy syndrome (PRES): focal motor status epilepticus	208			
III• 20	Cerebral cavernoma: non-convulsive focal status epilepticus	210			
III• 21	Cerebral cavernoma: <i>epilepsia partialis continua</i>	212			


CHAPTER



● Migraine and related conditions

IV• 1	Migraine with aura (1)	246	IV• 7	Syndrome of transient headache and neurologic deficits with cerebrospinal fluid lymphocytosis (HaNDL syndrome) (1)	258
IV• 2	Migraine with aura (2)	248	IV• 8	Syndrome of transient headache and neurologic deficits with cerebrospinal fluid lymphocytosis (HaNDL syndrome) (2)	260
IV• 3	Familial hemiplegic migraine (1)	250			
IV• 4	Familial hemiplegic migraine (2)	252			
IV• 5	Familial hemiplegic migraine: focal motor seizure (1)	254			
IV• 6	Familial hemiplegic migraine: focal motor seizure (2)	256			

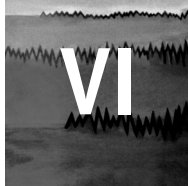
CHAPTER



● Dementia and degenerative disorders

V• 1	Advanced Alzheimer's disease (1)	264	V• 9	Creutzfeldt-Jakob disease (2)	280
V• 2	Advanced Alzheimer's disease (2)	266	V• 10	Creutzfeldt-Jakob disease (3)	282
V• 3	Senile myoclonic epilepsy (1)	268	V• 11	Creutzfeldt-Jakob disease (4)	284
V• 4	Senile myoclonic epilepsy (2)	270	V• 12	Creutzfeldt-Jakob disease (5)	286
V• 5	Cluster of seizures in a patient with vascular dementia	272	V• 13	Creutzfeldt-Jakob disease (6)	288
V• 6	Focal motor status epilepticus in a patient with neurodegenerative disease (1)	274	V• 14	Creutzfeldt-Jakob disease (7)	290
V• 7	Focal motor status epilepticus in a patient with neurodegenerative disease (2)	276	V• 15	Creutzfeldt-Jakob disease (8)	292
V• 8	Creutzfeldt-Jakob disease (1)	278	V• 16	Creutzfeldt-Jakob disease (9)	294
			V• 17	Postradiation encephalopathy	296

CHAPTER



● Neurosurgery and EEG

VI• 1	Brain tumor	300	VI• 13	Brain tumor: epilepsia partialis continua	324
VI• 2	Brain tumor: non-convulsive focal status epilepticus (1)	302	VI• 14	Head trauma	326
VI• 3	Brain tumor: non-convulsive focal status epilepticus (2)	304	VI• 15	Head trauma: cluster of seizure (1)	328
VI• 4	Brain tumor: non-convulsive focal status epilepticus (3)	306	VI• 16	Head trauma: cluster of seizures (2)	330
VI• 5	Brain tumor: non-convulsive focal status epilepticus (4)	308	VI• 17	Head trauma: focal motor status epilepticus (1)	332
VI• 6	Brain tumor: non-convulsive focal status epilepticus (5)	310	VI• 18	Head trauma: focal motor status epilepticus (2)	334
VI• 7	Brain tumor: non-convulsive focal status epilepticus (6)	312	VI• 19	Post-traumatic epilepsy: <i>epilepsia partialis continua</i> and focal seizure (1)	336
VI• 8	Brain tumor: aphasic status epilepticus (1)	314	VI• 20	Post-traumatic epilepsy: <i>epilepsia partialis continua</i> and focal seizure (2)	338
VI• 9	Brain tumor: aphasic status epilepticus (2)	316	VI• 21	Subdural hematoma: non-convulsive status epilepticus	340
VI• 10	Brain tumor: aphasic status epilepticus (3)	318			
VI• 11	Brain tumor: status epilepticus with minor motor signs (1)	320			
VI• 12	Brain tumor: status epilepticus with minor motor signs (2)	322			